

# Dexmedetomidine as adjunct in awake craniotomy – improvement or not?

Florian J. Raimann<sup>1</sup>, Elisabeth H. Adam<sup>1</sup>, Ulrich Strouhal<sup>1</sup>, Kai Zacharowski<sup>1</sup>,  
Volker Seifert<sup>2</sup>, Marie-Therese Forster<sup>2</sup>

<sup>1</sup>Department of Anaesthesiology, Intensive Care Medicine and Pain Therapy, University Hospital Frankfurt, Goethe University, Frankfurt, Germany

<sup>2</sup>Department of Neurosurgery, University Hospital Frankfurt, Goethe University, Frankfurt, Germany

## Abstract

**Background:** Over the last decade, awake craniotomy for tumor resection has become a standard to maximize tumor resection and minimize the risk of permanent neurological deficits. Different techniques and medication regimes have been tested for this procedure. Until today there is no consensus on the optimal approach. Therefore, we investigated the effect of dexmedetomidine as an adjunct in awake cerebral tumor surgery and evaluated our improved technique.

**Methods:** Data of patients who underwent awake craniotomy for tumor resection at our institution between 09/2006 and 05/2018 were retrospectively analyzed. All patients were kept awake after cortical mapping. After changing our standard anesthetic procedure from propofol/remifentanyl alone to propofol/remifentanyl and dexmedetomidine, we performed an evaluation of time to arousal, drug dosages, patients' cooperation and the occurrence of perioperative adverse events.

**Results:** Eighty-four patients received propofol/remifentanyl alone (SG). A further 17 patients additionally received dexmedetomidine following craniotomy in order to induce rapid arousal (DG). In the dexmedetomidine group a significantly reduced infusion time for propofol ( $169.2 \pm 47.4$  vs.  $212.9 \pm 63.3$  minutes;  $P = 0.008$ ) and non-significantly shorter time to arousal ( $12.0 [10.0/16.5]$  vs.  $15.0 [10.0/20.0]$  minutes;  $P = 0.271$ ) could be identified. In general, the overall procedure was very well tolerated by all patients.

**Conclusions:** The asleep-awake technique is a well-accepted and safe procedure. It allows continuous surveillance of the patient's neurological function during tumor resection and the postoperative phase, minimizing complications. In addition, our data show that the use of dexmedetomidine results in a shorter time to arousal.

**Key words:** awake craniotomy, dexmedetomidine, propofol, remifentanyl, brain tumor surgery, awake-asleep.

Anestezjologia Intensywna Terapia  
2020; 52, 1: 15–22

Otrzymano: 04.12.2019,  
zaakceptowano: 29.12.2019

## ADRES DO KORESPONDENCJI:

Florian J. Raimann, Department of Anaesthesiology, Intensive Care Medicine and Pain Therapy, University Hospital Frankfurt, Goethe University, Frankfurt, Germany, e-mail: Florian.Raimann@kgu.de

Over the last decade, awake craniotomy (AC) has become a commonly performed neurosurgical procedure for resection of brain tumors in eloquent areas [1]. By cortical and subcortical mapping functional areas can be localized in the awake patient, allowing maximal tumor resection up to functional boundaries [2, 3]. AC has been shown to result in fewer late neurological deficits [4, 5], shorter length of hospital stay [6, 7], and longer overall survival [5], the latter correlating directly with the extent of tumor resection [7]. However, the anesthesiological management for AC shows high variations between centers performing this procedure. So far, different anesthesiological approaches have been reported: asleep-awake-asleep (AAA), asleep-awake (AA), monitored anesthesia care (MAC) and conscious se-

dation (CS) [1, 6–16]. Not only applied techniques, but also used medication and airway devices, differ or have underlain changes and improvements over time [14, 17, 18]. Successful intraoperative mapping requires the patient to be fully awake and cooperative, challenging the anesthesiologist in charge. Extended knowledge in the field of neuroanesthesia, of used medication and of airway management is therefore required by the performing anesthesiologist. Strategies including local anesthesia for scalp blockade, advanced airway management, dedicated sedation protocols and skillful management of hemodynamics are essential [15].

At our institution, the asleep-awake technique has been used since 2006. By reviewing our experience with this technique we aimed to contribute to

a further standardization of neuroanesthetic management in AC and thus increase patients' safety.

## METHODS

### Study design and data collection

This observational retrospective single-center study was carried out in accordance with the Declaration of Helsinki. Ethical approval was provided by the local Ethics Committee of the UCT – University Hospital Frankfurt, Frankfurt, Germany (approval number SNO/10/2018). All patients of this study gave their written informed consent to the analysis of their clinical data and tumor tissue.

Between September 1<sup>st</sup>, 2006 and May 31<sup>st</sup>, 2018 data of all patients undergoing AC were collected and anonymized. Clinical information, including anesthesiological management, that had been extracted from institutional protocols, as well as surgical reports, was evaluated for each patient.

In our center, dexmedetomidine (DEX) was introduced as an adjunct for sedation in May 2016. Therefore, all patients who underwent AC since then were allocated to the DEX group (DG) and received propofol, remifentanyl and DEX. Patients receiving AC before May 2016 were assigned to the standard group (SG), receiving anesthesia/sedation by propofol and remifentanyl alone.

For all drug dosage, cumulative doses and periods of administration were registered from the beginning until the end of the surgical procedure, the latter being defined as the patient's arrival at the intensive care unit (ICU).

Four different time periods/durations were documented and analyzed. Time to arousal characterized the duration between discontinuing the anesthetic medication until the patient was fully awake and cooperative. The awake phase represented the period during which the patient was awake while undergoing the surgery, i.e. either until reintubation was necessary or until the end of surgery. The duration of surgery was defined as the time between incision and suture. The total duration characterized the total perioperative period from arrival in the operating room until leaving the operating room for transport to the ICU.

Objects of primary airway evaluation were Mallampati classification, thyromental distance (according to Patil) and extent of reinclination of the head. It was the choice of the responsible anesthetist whether to use a standard Macintosh endotracheal tube, laryngeal mask or laryngeal tube.

### Anesthetic management for the asleep-awake technique

All patients underwent standard noninvasive monitoring (arterial blood pressure measurement,

pulse oximetry and electrocardiography). After pre-oxygenation via a face mask for at least 3 minutes, sedation was induced either with fentanyl (Rotexmedica GmbH, Trittau, Germany) bolus (2–4  $\mu\text{g kg}^{-1}$ ) or remifentanyl (Aspen Pharma Trading Limited, Dublin, Ireland) as continuous infusion (0.25  $\mu\text{g kg}^{-1} \text{ min}^{-1}$ ), followed by propofol (Fresenius Kabi Deutschland GmbH, Bad Homburg, Germany) (3–5  $\text{mg kg}^{-1} \text{ h}^{-1}$ ). Then, either a laryngeal mask (LMA), laryngeal tube suction (LTS) or an endotracheal tube (ETT) was inserted for airway control. Patients intubated received rocuronium (Inresa Arzneimittel GmbH, Freiburg im Breisgau, Germany) (0.6  $\text{mg kg}^{-1}$ ). Thereafter, sedation was provided by intravenous infusions of propofol (4–9  $\text{mg kg}^{-1} \text{ h}^{-1}$ ) and remifentanyl (0.14–0.4  $\mu\text{g kg}^{-1} \text{ min}^{-1}$ ) to maintain anesthesia, and intra-arterial and a central venous catheters were placed. Sterofundin ISO (B. Braun, Melsungen, Germany) was used as continuous balanced crystalloid infusion as standard. If necessary, noradrenaline was administered to maintain mean arterial pressure above 70 mm Hg (9.3 kPa).

All patients were placed in a semi-lateral position, with the head fixed in a 3-pin skull clamp. Once positioned, infiltration of the pin sites, the operation field and an additional scalp nerve block were set, using ropivacaine (Fresenius Kabi) 40 mL 0.75% (300 mg) mixed with 200  $\mu\text{g}$  of adrenaline (InfectoPharm Arzneimittel und Consilium GmbH, Heppenheim, Germany).

Surgical preparation, draping and a final control using the surgical safety checklist followed. After craniotomy, the dura was first soaked with 1% lidocaine (Astra Zeneca GmbH, Wedel, Germany) and then opened. Now, and in accordance with the surgeon, general anesthesia was discontinued. As soon as the patient breathed spontaneously and showed signs of being awake, the LMA, LTS or ETT was removed.

In patients of the DG, DEX was initiated simultaneously to the discontinuation of propofol infusion at the time of bone flap removal. DEX was administered until the end of dura opening.

Cooperative patients underwent extensive cortical and subcortical mapping throughout the whole surgical procedure in order to define all functional boundaries of tumor resection.

Any intraoperative seizures were treated by pouring cold water on the brain and, if necessary, additionally by intravenous administration of levetiracetam (Declimed GmbH, Hamburg, Germany). Patients showing inadequate awakening, persistent seizures or insufficient spontaneous breathing were not extubated. In case of bradypnea, hypoventilation, central respiratory depression or  $\text{CO}_2$  accumulation, reintubation was performed

with the device of choice by the responsible anesthetist.

Intraoperative analgesia was performed by continuous administration of remifentanyl and bolus injection of metamizole. Once the surgical procedure was completed, patients were brought awake and spontaneously breathing to the ICU for postoperative surveillance.

### Statistical analyses

All statistical analyses were performed using SigmaPlot 12 (Systat Software GmbH, Erkrath, Germany). Depending on the distribution of data (determined via the Shapiro-Wilk test), Student's *t*-test or the Mann-Whitney rank sum test was used to compare data. The  $\chi^2$  or Fisher exact test was used to detect differences between the proportions of patients with respect to categorical data. Values were expressed as number (count, percent), mean  $\pm$  SD, or median (25<sup>th</sup> and 75<sup>th</sup> percentiles, IQR), as appropriate. All tests were two-sided, and the level of significance was set to  $P < 0.05$ .

### RESULTS

In total, 122 patients underwent AC between September 1<sup>st</sup>, 2006 and May 31<sup>st</sup>, 2018 in our Department of Neurosurgery. Due to missing data (Figure 1), 21 patients had to be excluded from the study, resulting in a final analysis of 101 patients.

After changing our standard operating procedure in May 2016 all patients undergoing AC received DEX as an adjunct, resulting in 17 patients allocated to the DG. Although the number of patients in the SG and DG differed, there were no statistically significant differences in their baseline characteristics (Table 1).

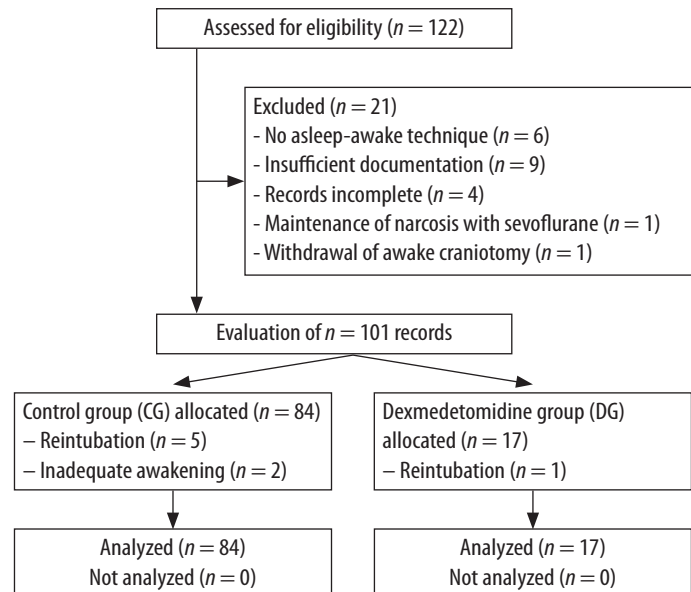


FIGURE 1. Flowchart including exclusion criteria and complications

### Use of anesthetics

All anesthetics used during the surgical procedure are listed in Table 2. Compared to patients in the SG, patients in the DG showed a significantly shorter period of propofol administration ( $P = 0.008$ ). However, the total dose of propofol was nearly identical in both groups ( $P = 0.789$ ), as propofol was administered at a significantly increased rate in the DG compared to the SG ( $P < 0.001$ ) (Table 2). Patients in both groups received propofol during the awake phase on an individual basis due to anxious behavior.

The period of remifentanyl administration did not differ between groups ( $P = 0.484$ ). Nevertheless, the patients in the DG received a cumulatively higher dose ( $P = 0.023$ ) as a result of an increased infusion

TABLE 1. Demographic data

Factor	Total (N = 101)	SG (n = 84)	DG (n = 17)	P-value
Age (years)	44.0 (32.3/54.4)	45.0 (31.9/54.3)	40.3 (32.5/58.3)	0.803 <sup>†</sup>
Sex, n (%)				
Male	70 (69)	59 (70)	11 (65)	
Female	31 (31)	25 (30)	6 (35)	
Body mass (kg)	80.0 (72.5/88.0)	80.5 (72.3/88.0)	80.0 (73.0/86.0)	0.659 <sup>†</sup>
Height (cm)	177.7 $\pm$ 8.7	177.4 $\pm$ 8.8	179.2 $\pm$ 8.1	0.447 <sup>‡</sup>
BMI (kg m <sup>-2</sup> )	24.8 (22.9/26.7)	24.8 (22.9/27.2)	24.4 (23.1/26.0)	0.605 <sup>†</sup>
ASA, n (%)				
I	0 (0)	0 (0)	0 (0)	
II	85 (83)	74 (88)	11 (65)	
III	16 (16)	10 (12)	6 (35)	
IV	0 (0)	0 (0)	0 (0)	

SG – standard group, DG – dexmedetomidine group, ASA – American Society of Anesthesiologist = Classification for perioperative risk

<sup>†</sup>Mann-Whitney U test, <sup>‡</sup>Using Student's *t*-test

Values are depicted in median (IQR), mean  $\pm$  SD or count/percentage

TABLE 2. Drug administration

Drug	Phase	Description	Total (N = 101)	SG (n = 84)	DG (n = 17)	P-value
Propofol	GA	Propofol duration (min)	205.5 ± 62.9	212.9 ± 63.3	169.2 ± 47.4	0.008**
		Propofol (mg)	1848.3 (1324.5/2322.2)	1850.0 (1302.0/2426.3)	1848.3 (1425.7/2193.2)	0.789†
		∅ Diso (mg kg <sup>-1</sup> h <sup>-1</sup> )	6.8 (6.2/7.8)	6.6 (6.1/7.5)	8.5 (7.4/9.0)	< 0.001**
	Awake	Propofol, n (%)				0.126 <sup>§</sup>
		Yes	27 (27)	25 (30)	Yes (n = 2; 12%)	
		No	74 (73)	59 (70)	No (n = 15; 88%)	
		Propofol duration (min)	0.0 (0.0/17.5)	0.0 (0.0/23.8)	0.0 (0.0/0.0)	0.144†
Propofol (mg)	0.0 (0.0/26.5)	0.0 (0.0/35.0)	0.0 (0.0/0.0)	0.127†		
∅ Propofol (mg kg <sup>-1</sup> h <sup>-1</sup> )	0.8 (0.7/0.9)	0.8 (0.7/0.9)	0.8 (0.8/0.8)	0.853†		
Remifentanyl	GA	Remifentanyl duration (min)	195.0 (157.5/235.0)	195.0 (151.3/237.8)	200.0 (177.5/225.0)	0.484†
		Remifentanyl (µg)	3540.0 (2371.0/5850.0)	3338.8 (2277.1/5212.7)	5460.0 (3094.5/6443.8)	0.023**
		∅ Remifentanyl (µg kg <sup>-1</sup> min <sup>-1</sup> )	0.25 ± 0.09	0.23 ± 0.09	0.32 ± 0.08	< 0.001**
	Awake	Remifentanyl, n (%)				0.345 <sup>§</sup>
		Yes	888 (87)	72 (86)	Yes (n = 16; 94%)	
		No	13 (13)	12 (14)	No (n = 1; 6%)	
		Remifentanyl duration (min)	110.0 (37.5/190.0)	125.0 (45.3/195.0)	70.0 (22.5/100.0)	0.032**
Remifentanyl (µg)	459.0 (215.0/777.4)	461.0 (205.5/798.8)	360.0 (221.6/540.0)	0.464†		
∅ Remifentanyl (µg kg <sup>-1</sup> min <sup>-1</sup> )	0.05 (0.04/0.09)	0.06 (0.03/0.08)	0.05 (0.05/0.14)	0.217†		
Fentanyl	Bolus	Fentanyl (mg)	0.2 (0.0/0.3)	0.2 (0.0/0.3)	0.2 (0.15/0.3)	0.446†
		Fentanyl, n (%)				0.215 <sup>§</sup>
		Yes	68 (67)	52 (62)	Yes (n = 16; 94%)	
		No	33 (33)	32 (38)	No (n = 1; 6%)	
Dexdor	GA	Dex. (min)	–	–	65.0 (30.0/110.5)	–
		Dex. (µg)	–	–	64.1 (26.5/132.7)	–
		∅ Dex. (µg kg <sup>-1</sup> h <sup>-1</sup> )	–	–	0.7 (0.7/1.0)	–

SG – standard group, DG – dexmedetomidine group, Dex. – dexmedetomidine, GA – general anesthesia: phase of procedure between induction of narcosis until intraoperative awakening. Awake – phase of procedure from intraoperative awakening until completion of transport to intensive care unit. Propofol, remifentanyl, and Dexdor were depicted in two categories: GA and Awake

†Mann-Whitney U-test, †Student's t-test, †χ<sup>2</sup>-test, \*significant P values (P < 0.05)

Values are depicted in median (IQR), mean ± SD or count/percentage

rate ( $P < 0.001$ ). In the awakening phase, analgesia with remifentanyl was performed in the SG over a significantly longer period of time ( $P = 0.032$ ), but there was still no significant difference regarding total dosage comparing both groups ( $P = 0.464$ ) (Table 2). Fentanyl as an opioid for induction of anesthesia was used in both groups. Its dosage also did not differ between groups ( $P = 0.446$ ).

### Intraoperative complications

In total, 12 patients (12%) showed intraoperative seizures, of whom eleven patients (13%) were treated in the SG and one patient (6%) in the DG, which did not result in significant group difference ( $P = 0.402$ ).

In six patients (6%), all from the SG group, initial intubation difficulties occurred; in four patients the airway was finally secured with a laryngeal mask. In these four patients the preoperative airway evaluation revealed a Cormack and Lehane score of III. In one case an ETT was used and in one

case a LTS. These two patients presented an unexpected difficult airway. During surgery, failed extubation occurred in two patients (2%), both treated in the SG. Most importantly, reintubation was required in six patients (6%), of whom five were in the SG and one in the DG. For reintubation LMA were used in five (83%) cases, and in one patient an ETT was inserted.

### Time periods

Analyzing the duration of different periods with surgery revealed no significant differences between the two groups (Table 3). A non-significantly shorter duration of arousal was found in the DG (SG vs. DG; 15 min. vs. 12 min.;  $P = 0.271$ ).

### Airway management

No difference was found between the two groups regarding Mallampati classification, thyromental distance according to Patil ( $P = 0.554$ ) or extent of reclinatio

TABLE 3. Durations of different intraoperative periods

Phase	Total (N = 101)	SG (n = 84)	DG (n = 17)	P-value
Median duration of arousal (min)	15.0 (10.0/20.0)	15.0 (10.0/20.0)	12.0 (10.0/16.5)	0.271 <sup>†</sup>
Median duration of awake phase (min)	210.0 (165.0/262.5)	215.0 (170.0/253.8)	195.0 (150.0/335.0)	0.888 <sup>†</sup>
Median duration of surgery (min)	293.0 (252.0/353.5)	301.0 (252.0/351.0)	266.0 (235.0/424.0)	0.747 <sup>†</sup>
Median duration of overall procedure (min)	480.0 (430.5/567.5)	487.0 (430.3/563.8)	467.0 (428.5/612.5)	0.992 <sup>†</sup>

SG – standard group, DG – dexmedetomidine group

<sup>†</sup>Mann-Whitney U test

Values are depicted in median (IQR)

TABLE 4. Airway management

Parameter	Total (N = 101)	SG (n = 84)	DG (n = 17)	P-value
Mallampati classification, n (%)				
1	60 (67)	48 (66)	12 (71)	
2	26 (29)	21 (29)	5 (29)	
3	4 (4)	4 (5)	0 (0)	
4	0 (0)	0 (0)	0 (0)	
Thyromental distance (Patil) (cm)	6.5 (6.0/6.6)	6.5 (6.0/6.9)	6.5 (6.0/6.6)	0.554 <sup>  </sup>
Reclination normal range, n (%)				0.827 <sup>‡</sup>
Yes	80 (99)	66 (99)	14 (100)	
No	1 (1)	1 (1)	0 (0)	
Primary airway, n (%)				
LMA	75 (81)	60 (78)	15 (94)	
ITN	17 (18)	16 (21)	1 (6)	
LTS	1 (1)	1 (1)	0 (0)	
Intubation difficulties, n (%)				0.312 <sup>‡</sup>
Yes	6 (6)	6 (7)	0 (0)	
No	94 (94)	77 (93)	17 (100)	
Failed extubation, n (%)				1.000 <sup>‡</sup>
Yes	2 (2)	2 (2)	0 (0)	
No	99 (98)	82 (98)	17 (100)	
Reintubation necessary, n (%)				0.991 <sup>§</sup>
Yes	6 (6)	5 (6)	1 (6)	
No	95 (94)	79 (94)	16 (94)	
Reintubation device, n (%)				0.167 <sup>‡</sup>
LMA	5 (83)	5 (100)	0 (0)	
ITN	1 (17)	0 (0)	1 (100)	
Reintubation difficulties, n (%)				1.000 <sup>‡</sup>
Yes	0 (0)	0 (0)	0 (0)	
No	6 (100)	5 (100)	1 (100)	

SG – standard group, DG – dexmedetomidine group, LMA – laryngeal mask, ITN – tracheal intubation, LTS – larynx tube

Mallampati: score to evaluate difficult airway. Reclination: ability to recline the head with/without restrictions. Intubation difficulties: difficulties to place airway device

<sup>‡</sup>Student's *t*-test, <sup>§</sup> $\chi^2$  test, <sup>||</sup>Fisher exact test

tubation was necessary in three patients due to refractory intraoperative seizure and in three patients due to respiratory exhaustion. No reintubation was requested by any patient.

Table 4 shows characteristics of airway management including used devices for securing the airway.

## DISCUSSION

For this observation over a period of 12 years, data from 101 patients undergoing AC for brain tumor surgery were evaluated. The anaesthesiological management of AA using propofol and remifentanyl, optionally in combination with DEX, enabled suf-

ficient protection of the respiratory tract in all patients. Further, all patients showed a rapid arousal for cortical mapping. The entire procedure was well tolerated by all patients and a precise neurological monitoring of the neurological condition was achieved as the patients stayed awake for the rest of the surgery.

### Considerations regarding different anesthesiological techniques

According to the literature, different anesthetic techniques have been used for AC during the last decades. However, data for the use of GA for cerebral tumor surgery in eloquent areas show worse outcomes and higher total inpatient costs compared to awake craniotomies [19].

A meta-analysis evaluating the usefulness of intraoperative mapping confirmed that its use resulted in a reduction in morbidity and in an increase in extent of tumor resection compared to a cohort undergoing surgery without intraoperative mapping [4]. However, in order to perform reliable intraoperative mapping an awake and cooperative patient is needed. This can be achieved in different ways. For the asleep-awake-asleep technique, patients are under GA at the beginning, requiring a secure airway and controlled ventilation [8, 9, 15, 16]. On the one hand, this may be advantageous for the patient, not experiencing the stressful phase from placing on the table, clamping in the Mayfield holder, preparation for craniotomy itself and, later on, the intraoperative phase after cortical mapping. On the other hand, it may be difficult to re-secure the airway of a patient positioned in the Mayfield clamp because access to the patient's head is often restricted and reinclination of the head is impossible.

Different possibilities for securing the airway during AC have been evaluated. According to the meta-analysis of Stevanovic *et al.* most common is the LM, facemask or nasal cannula [15]. At our department, LMA and endotracheal tubes are the most commonly used devices, but in recent years there has been a trend towards more frequent use of LMA (Table 4). Furthermore, GA and reintubation immediately after tumor resection restricts prompt postoperative neurological examination. A first postoperative neurological examination will then only be possible after extubation in the intensive care unit. This leads to a variable time frame without any surveillance of neurological deficits. In our study, six patients needed reintubation, which could be performed without any complications.

Another approach to perform AC is monitored anesthesia care or the conscious sedation technique. During this procedure patients are kept in

different levels of sedation with preserved spontaneous breathing [8, 9, 13, 15, 20], and therefore no airway safety is required. Nevertheless, keeping the patient in (deep) sedation with sufficient spontaneous breathing is challenging. An increase in  $\text{paCO}_2$  by bradypnea may result in raised intracerebral pressure leading to brain swelling and herniation after dural incision and opening. The patient's hyperventilation may reduce this effect, but this requires the patient to be cooperative [7]. Moreover, since the patient is awake during the whole procedure, even in sedation, he might experience the surgical procedure as an increased stress level.

In our department, we have brought together the benefits of different techniques to achieve the best possible advantages in terms of neurological monitoring and patient comfort. The AA technique allows a stressless insertion of the central venous catheter and artery line, as well as positioning and placing the patient in the Mayfield clamp. Furthermore, controlled ventilation allows one to control the end-tidal  $\text{CO}_2$ , which allows for a compensatory mechanism to react on brain swelling after dura incision. As mentioned earlier, the patients' wakefulness after tumor resection provides an excellent possibility to assess his or her neurological condition. In addition, the prolonged awake period, which was a median of 210.0 minutes (IQR 165.0/262.5) in our studied cohort, was very well tolerated by all patients.

### Medication

Besides techniques, also used medication differs between centers performing AC, and several different combinations have been reviewed [7–9, 11–13]. At an optimum, drugs should have a fast on- and offset, should not influence the patients' neurocognitive function during intraoperative mapping, and should not have a depressive effect on the cardiovascular and respiratory system.

If GA is part of the performed technique, propofol and remifentanyl [7, 8, 11, 12, 15, 16, 21] are most commonly used while volatile anesthetics and fentanyl are less common [9]. Fentanyl, as well as alfentanil and sufentanil, showed a proconvulsive effect, making remifentanyl the opioid of choice for AC [13, 16]. Moreover, intravenous anesthesia by manually controlled infusion (MCI) should be rejected in favor of target-controlled infusion (TCI) when conducting AC. As demonstrated by Wang *et al.* TCI group patients have a significantly shorter intraoperative awakening time. The highest bispectral index score (BIS) values appeared during the awake phase in the TCI group and the mean heart rate and arterial pressure were more stable in the TCI group in comparison to the MCI group [16].

Using BIS monitoring during AC may be beneficial to shorten post-anesthetic recovery due to reduced cumulative doses of anesthetics. Conte *et al.* found higher BIS values at the end of the asleep phase associated with shorter time to LMA removal [21].

Most recently, DEX as an anxiolytic, sedative and anesthetic drug has been introduced in AC [13] and was used as an additive in the beginning [22, 23]. DEX is a lipophilic imidazole derivate that selectively binds on pre- and postsynaptic  $\alpha_2$ -receptors and acts as an agonist. It has an opioid-sparing effect and therefore results in less respiratory distress than propofol. Moreover, it has not only been demonstrated that DEX allows successful electrocorticography (ECoG) monitoring during AC [14], but also that DEX leads to a shorter duration of arousal compared to propofol [24], as could be confirmed by our data. Thus, patients of the DG were awake after 12.0 min (IQR 10.0/16.5) compared to 15.0 min (IQR 10.0/20.0) in patients of the SG.

### Limitations

The main limitation of this study is its retrospective nature. With the introduction of DEX only recently, the number of patients receiving DEX did finally not allow for a powerful statistical analysis. Therefore, and above all due to patients' heterogeneous characteristics such as tumor histology, tumor location, tumor volume, age and clinical state, matching of patients receiving DEX with patients in the control group was not possible. Moreover, although surgery was conducted by the same dedicated team of neurosurgeons over the complete study period, different anesthesiological teams were involved in patients' treatment. We propose to perform a large multicenter randomized controlled trial in order to further evaluate the AA technique in combination with DEX. This would allow us to correct for the patients' inherent characteristics and eliminate possible bias.

### CONCLUSIONS

All mentioned approaches have contributed to optimize the procedure for AC over the years. A notable benefit of the AA technique is the ability to assess the patients' neurological state from arousal until the end of surgery and immediately thereafter. Thus, planned reintubation is no longer necessary, avoiding the risk of airway incidents in this context. The AA technique is safe and well tolerated by all patients. Furthermore, AA is beneficial to AAA or MAC, due to reduced stress during the initial phase of surgery. Using DEX as an adjunct to propofol and remifentanyl the duration of patients' arousal can be decreased under successful ECoG monitoring, and

without influencing patients' respiratory state, resulting in increased patients' safety.

### ACKNOWLEDGEMENTS

1. Previous presentation: DAC – Deutscher Anästhesie Congress, Nürnberg, Germany, April 2018; EANS – European Association of Neurosurgical Societies, Brussels, Belgium, October 2018; DGNC – Deutsche Gesellschaft für Neurochirurgie, Würzburg, Germany, May 2019.
2. Financial support and sponsorship: none.
3. Conflict of interest: none.

### REFERENCES

1. Surbeck W, Hildebrandt G, Duffau H. The evolution of brain surgery on awake patients. *Acta Neurochir (Wien)* 2015; 157: 77-84. doi: 10.1007/s00701-014-2249-8.
2. Sanai N, Mirzadeh Z, Berger MS. Functional outcome after language mapping for glioma resection. *N Engl J Med* 2008; 358: 18-27. doi: 10.1056/NEJMoa067819.
3. Duffau H, Lopes M, Arthuis F, et al. Contribution of intraoperative electrical stimulations in surgery of low grade gliomas: a comparative study between two series without (1985-96) and with (1996-2003) functional mapping in the same institution. *J Neurol Neurosurg Psychiatry* 2005; 76: 845-851. doi: 10.1136/jnnp.2004.048520.
4. De Witt Hamer PC, Robles SG, Zwinderman AH, Duffau H, Berger MS. Impact of intraoperative stimulation brain mapping on glioma surgery outcome: a meta-analysis. *J Clin Oncol* 2012; 30: 2559-2565. doi: 10.1200/JCO.2011.38.4818.
5. Sacko O, Lauwers-Cances V, Brauge D, Sesay M, Brenner A, Roux FE. Awake craniotomy vs surgery under general anesthesia for resection of supratentorial lesions. *Neurosurgery* 2011; 68: 1192-1198; discussion 1198-1999. doi: 10.1227/NEU.0b013e31820c02a3.
6. Brown T, Shah AH, Bregy A, et al. Awake craniotomy for brain tumor resection: the rule rather than the exception? *J Neurosurg Anesthesiol* 2013; 25: 240-247. doi: 10.1097/ANA.0b013e318290c230.
7. Hervey-Jumper SL, Li J, Lau D, et al. Awake craniotomy to maximize glioma resection: methods and technical nuances over a 27-year period. *J Neurosurg* 2015; 123: 325-339. doi: 10.3171/2014.10.JNS141520.
8. Dilmen OK, Akcil EF, Oguz A, Vehid H, Tunali Y. Comparison of conscious sedation and asleep-awake-asleep techniques for awake craniotomy. *J Clin Neurosci* 2017; 35: 30-34. doi: 10.1016/j.jocn.2016.10.007.
9. Eseonu CI, ReFaey K, Garcia O, John A, Quiñones-Hinojosa A, Tripathi P. Awake craniotomy anesthesia: a comparison of the monitored anesthesia care and asleep-awake-asleep techniques. *World Neurosurg* 2017; 104: 679-686. doi: 10.1016/j.wneu.2017.05.053.
10. Keifer JC, Dentchev D, Little K, Warner DS, Friedman AH, Borel CO. A retrospective analysis of a remifentanyl/propofol general anesthetic for craniotomy before awake functional brain mapping. *Anesth Analg* 2005; 101: 502-508. doi: 10.1213/01.ANE.0000160533.51420.44.
11. Meng L, McDonagh DL, Berger MS, Gelb AW. Anesthesia for awake craniotomy: a how-to guide for the occasional practitioner. *Can J Anaesth* 2017; 64: 517-529. doi: 10.1007/s12630-017-0840-1.
12. Olsen KS. The asleep-awake technique using propofol-remifentanyl anaesthesia for awake craniotomy for cerebral tumours. *Eur J Anaesthesiol* 2008; 25: 662-669.
13. Prontera A, Baroni S, Marudi A, et al. Awake craniotomy anesthetic management using dexmedetomidine, propofol, and remifentanyl. *Drug Des Devel Ther* 2017; 11: 593-598. doi: 10.2147/DDDT.S124736.
14. Souter MJ, Rozet I, Ojemann JG, et al. Dexmedetomidine sedation during awake craniotomy for seizure resection: effects on electrocorticography. *J Neurosurg Anesthesiol* 2007; 19: 38-44. doi: 10.1097/01.ana.0000211027.26550.24.
15. Stevanovic A, Rossaint R, Veldeman M, Bilotta F, Coburn M. Anaesthesia management for awake craniotomy: systematic review and meta-analysis. *PLoS One* 2016; 11: e0156448. doi: 10.1371/journal.pone.0156448.
16. Wang X, Wang T, Tian Z, Brogan D, Li J, Ma Y. Asleep-awake-asleep regimen for epilepsy surgery: a prospective study of target-controlled

- infusion versus manually controlled infusion technique. *J Clin Anesth* 2016; 32: 92-100. doi: 10.1016/j.jclinane.2015.11.014.
17. De Sloovere V, De Deyne C, Wuyts J, Heylen R. Bispectral index monitoring during asleep-awake technique for craniotomy. *Eur J Anaesthesiol* 2009; 26: 443-444. doi: 10.1097/EJA.0b013e32831bc70c.
  18. Sivasankar C, Schlichter RA, Baranov D, Kofke WA. Awake craniotomy: a new airway approach. *Anesth Analg* 2016; 122: 509-511. doi: 10.1213/ANE.0000000000001072.
  19. Eseonu CI, Rincon-Torroella J, ReFaey K, Quiñones-Hinojosa A. The cost of brain surgery: awake vs asleep craniotomy for perirolandic region tumors. *Neurosurgery* 2017; 81: 307-314. doi: 10.1093/neuros/nyx022.
  20. Berkenstadt H, Perel A, Hadani M, Unofrievich I, Ram Z. Monitored anesthesia care using remifentanyl and propofol for awake craniotomy. *J Neurosurg Anesthesiol* 2001; 13: 246-249. doi: 10.1097/0008506-200107000-00013.
  21. Conte V, Magni L, Songa V, et al. Analysis of propofol/remifentanyl infusion protocol for tumor surgery with intraoperative brain mapping. *J Neurosurg Anesthesiol* 2010; 22: 119-127. doi: 10.1097/ANA.0b013e3181c959f4.
  22. Ard JL Jr, Bekker AY, Doyle WK. Dexmedetomidine in awake craniotomy: a technical note. *Surg Neurol* 2005; 63: 114-116. 10.1016/j.surneu.2004.02.029.
  23. Bekker AY, Kaufman B, Samir H, Doyle W. The use of dexmedetomidine infusion for awake craniotomy. *Anesth Analg* 2001; 92: 1251-1253. doi: 10.1097/0000539-200105000-00031.
  24. Shen SL, Zheng JY, Zhang J, et al. Comparison of dexmedetomidine and propofol for conscious sedation in awake craniotomy: a prospective, double-blind, randomized, and controlled clinical trial. *Ann Pharmacother* 2013; 47: 1391-1399. doi: 10.1177/1060028013504082.